

## EFFICACY OF HYALURONIC ACID GEL WITH CORONALLY ADVANCED FLAP IN THE TREATMENT OF GINGIVAL RECESSION: A RANDOMIZED CLINICAL TRIAL

HADI AHMED KHIDER (B.D.S)\*  
SAEED A. MUHAMMAD, B.D.S, M.Sc., Ph.D. (Periodontics)\*\*

*Submitted 21 June 2025; accepted 10 October 2025*

### ABSTRACT

**Background:** Gingival recession (GR) impairs aesthetics and causes root sensitivity, requiring predictable root coverage. The coronally advanced flap (CAF) is the gold standard for Miller Class I defects; however, it yields variable outcomes. This study aimed to evaluate adjunctive 0.8% or 0.2% hyaluronic acid (HA) gel for enhancing CAF efficacy in GR treatment.

**Materials and methods:** This double-blind, three-arm, randomized controlled clinical trial was conducted on 30 patients with localized Miller Class I gingival recession ( $\geq 2$  mm) who were randomized into three groups: Group A (n = 10, CAF + 0.8% HA). Group B (n = 10, CAF + 0.2% HA). Group C (n = 10, CAF alone). All clinical parameters, including recession depth (RD), width of keratinized gingiva (WKG), probing pocket depth (PPD), clinical attachment level (CAL), plaque index (PI), gingival index (GI) and root coverage percentage (RC%), were measured at baseline and one-month and three-month follow-up.

**Results:** After 3 months, the three groups demonstrated statistically significant improvement from baseline ( $p < 0.05$ ). Group A showed the greatest reduction in RD (from 3mm to 1mm) and the highest RC (66.7%) followed by group B with RD reduction (3mm to 1.75mm) and RC (50%), and group C with RD reduction (3.5mm to 2.75 mm) and RC (15.5%). CAL gain and PPD reduction were also significantly greater in group A than the other groups. No statistically significant intergroup differences were observed in WKG, PI, or GI.

**Conclusion:** In the treatment of Miller Class I gingival recessions, the adjunctive use of 0.8% HA with CAF significantly improves root coverage, RD reduction, and CAL gain over both 0.2% HA and CAF alone.

**Duhok Med J 2025; 19 (2): 87-100**

**Keywords:** Gingival recession, Coronally advanced flap, Hyaluronic acid, Root coverage.

The fundamental goal of dental and periodontal treatment is to maintain the natural dentition as healthy, comfortable, functional, and aesthetically pleasing as possible. Gingival recession is a common, undesirable clinical condition that increases with age<sup>[1]</sup>, and its aetiology is multifactorial. Local factors such as dental plaque-induced periodontitis and traumatic tooth brushing often combine with anatomical factors, including malposition of teeth and an aberrant frenum. Root sensitivity, caries, and aesthetic issues are

clinical implications of GR, and surgical intervention is typically required to restore function and appearance<sup>[2]</sup>.

Among several surgical techniques, CAF has become the most widely accepted approach for treating gingival recessions due to its effectiveness, predictable results, and less invasiveness. CAF is considered the gold standard for Miller Class I/II recessions, according to American Academy of Periodontology (AAP) guidelines<sup>[3]</sup>.

\* Dept. of Periodontics, College of Dentistry, Duhok University, Duhok, Iraq.

\*\* Dept. of Periodontics, Chairman of Kurdistan Dental Association Duhok Branch, Dean of College of Dentistry, Duhok University, Duhok, Iraq. Mobile: +967504577151

Corresponding Author Dr. Hadi Ahmed Khider, DDS. E-mail: hadi.khider88@gmail.com

Compared to connective tissue graft, which needs further surgery, CAF avoids donor site morbidity and is more acceptable to the patient. However, the CAF result isn't always quantified as it is influenced by patient-specific factors, surgical method, and defect factors<sup>[4]</sup>.

To enhance healing outcomes, recent studies have utilized biologic materials such as hyaluronic acid as an adjunct to CAF. HA is a polysaccharide in the extracellular matrix of human connective tissues. HA has well-documented biological functions, including the proliferation of mesenchymal stem cells, fibroblasts, and chondrocytes, maintaining tissue hydration and lubrication, which play a key role in periodontal regeneration<sup>[5,6]</sup>. Clinical trials have begun to support HA use with CAF showing improved results. HA adjunctivity with CAF enhances clinical attachment level and reduces recession depth<sup>[7,8]</sup>.

Although of these promising findings, a key question remains unanswered: what is the optimum concentration of HA for achieving the best clinical results? Some clinical studies have utilized lower concentrations (e.g., 0.2%)<sup>[9]</sup>, while others have used higher concentrations (e.g., 0.8%)<sup>[10]</sup> with mixed results. This intense disagreement leaves a significant gap in the literature.

### **The study hypothesis and objective**

Based on the identified gap in the literature, the hypothesis is that at 3 months, Group A (0.8% HA) will show a significantly greater reduction in RD compared to Groups B and C. according to the hypothesis, the current study is the first controlled trial that aims to directly compares the clinical effects and outcomes of 0.2% and 0.8% HA gels as adjuncts to CAF, with CAF alone as the control. Additionally, this study addresses a regional need as Kurdistan, Iraq, has limited access to periodontal specialists and cost barriers to treatment. Given the availability of hyaluronic acid and patients' desire to avoid a second surgery, optimizing

its use with CAF may be a more practical and acceptable approach for gingival recession treatment in local clinics.

## **MATERIALS AND METHODS**

### **Setting and time of the study**

The present study was conducted in the Periodontics Department of the College of Dentistry at the University of Duhok in Duhok city. The patients were attending the Department of Periodontics. Data was gathered for the research between November 2024 and June 2025. The CONSORT 2010 Statement was used as a guide for the writing of this report.

### **Sample size calculation**

The sample size was calculated using G\* power software (version 3.1.9.4, Heinrich Heine University Düsseldorf, Germany) for a significance level of 5%, with power = 95%, effect size = 0.8, and 3 groups. The analysis indicated a required total sample size of 30 participants (10 per group)

### **Study design and population**

The current study design was a double-blinded, three-arm, parallel-group randomized controlled clinical trial. Eighty patients attending the Periodontics Department at the University of Duhok College of Dentistry were screened for eligibility. Fifty patients met the inclusion criteria. After providing detailed explanations of the study protocol, 38 patients gave written informed consent using forms in both Kurdish and Arabic. The recruitment flow is detailed in Figure 1. Table 4.

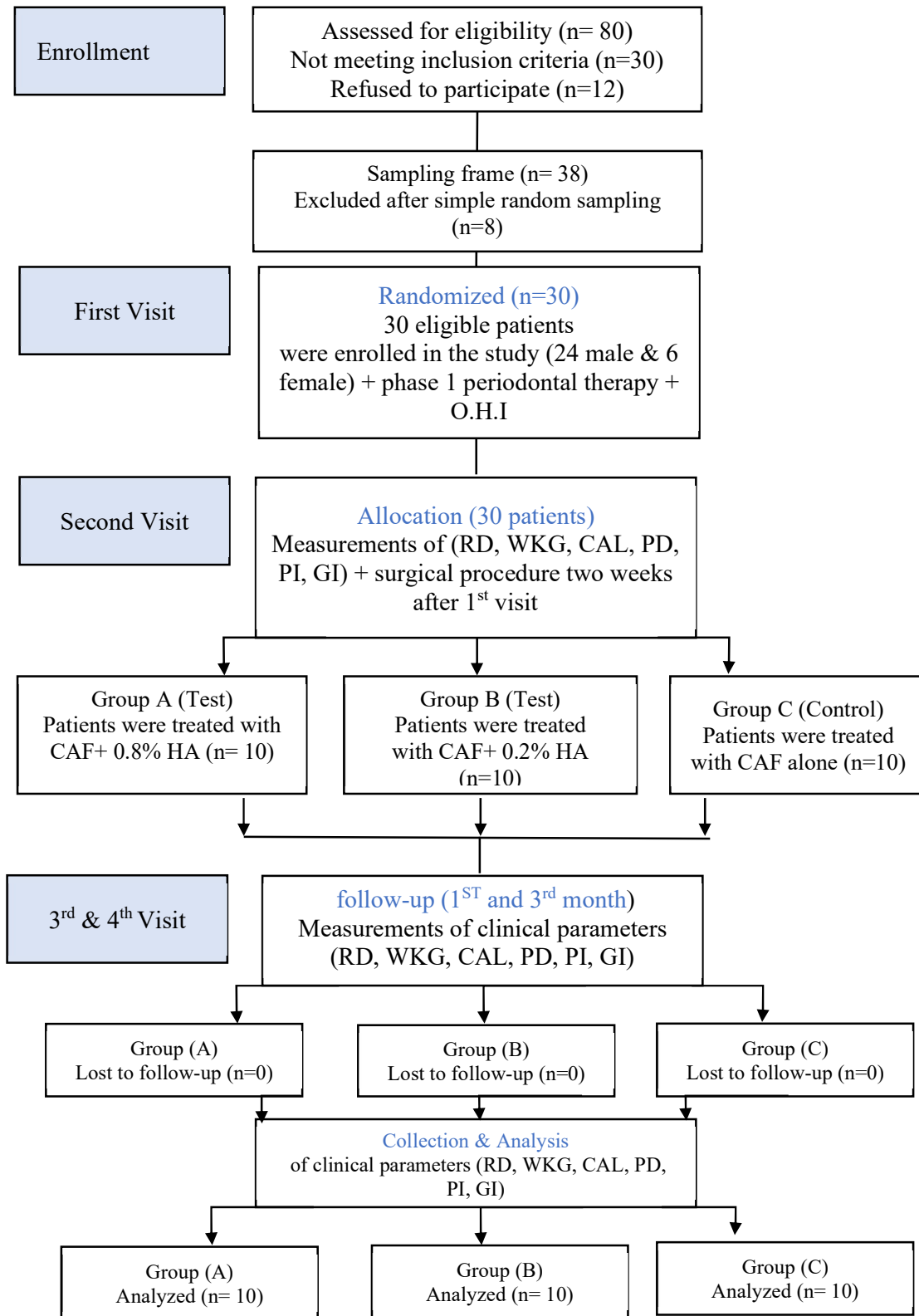


Figure 1: Recruitment flow chart

#### Selection criteria

Participants included in this study had localized gingival recession  $\geq 2$  mm, classified as Miller Class I recession/RT 1, with a minimal 1 mm of keratinized gingiva apical to the recession. Only systemically healthy patients (18-60 years) with good oral hygiene ( $PI \leq 1$ ,  $GI \leq 1$ ), normal occlusal relationship, and no cervical caries or restoration. Exclusion criteria included uncontrolled systemic disease (e.g., diabetes mellitus), medication **interfering with healing or gingival health** (e.g., phenytoin) or anticoagulants, **known allergy to hyaluronic acid, lidocaine, or any study materials**, Pregnancy or lactation, **periodontal surgery in the target area within the past 6 months or active infections** (e.g., periapical abscess), smokers or tobacco product users, and Poor compliance with oral hygiene or inability to attend follow-ups.

#### Ethical Considerations:

Approved by the Duhok Directorate of Health research ethics committee (reference number: 30102024-9-5). Participants received clear explanations of the study's purpose, risks (temporary pain, swelling), and benefits (improved root coverage and aesthetics). Additionally, written consent forms were provided in both Kurdish and Arabic, with the option to withdraw at any time.

#### Randomization and Patient Grouping:

The study employed three treatment modalities: group A was treated with CAF plus 0.8% HA, group B was treated with CAF plus 0.2% HA, and group C was treated with CAF alone. patients were randomly assigned to one of three groups (A, B, C) by an independent statistician using random allocation software (version 3.8.1) with a 1:1:1 allocation ratio. The allocation sequence was concealed via sequentially numbered, opaque, and sealed envelopes opened immediately before surgery. A **single trained surgeon** performed all procedures using a standardized protocol.

#### Clinical measurements

A blinded examiner took the following clinical measurements for each tooth at baseline, one month, and three months after surgery, using a calibrated periodontal probe (UNC-15). During data analysis, the examiners maintained blinding via coded patient IDs.

The measurements were defined as follows: RD defined as the distance from the cemento-enamel Junction (CEJ) to the gingival margin at the mid-facial site on the considered tooth<sup>[11]</sup>, WKG as the distance from the mucogingival junction (MGJ) to the gingival margin at the mid-facial point<sup>[12]</sup>, PPD as the distance from the gingival margin's most apical point to the pocket's base<sup>[13]</sup>, CAL as the distance from the base of the periodontal pocket to the CEJ<sup>[14]</sup>.

PI accumulation scored from 0 to 3 as: (0: no plaque, 1: plaque adheres to the gingival margin but not seen by the naked eye, 2: plaque seen by the naked eye, 3: heavy plaque)<sup>[15]</sup>. GI scored from 0 to 3 as: (0: normal gingiva, 1: slightly changed color, no bleeding on probing, 2: redness and bleeding on probing, 3: spontaneous bleeding, severe inflammation)<sup>[16]</sup>.

#### Pre-Surgical Preparation:

After enrolling the eligible patients, their personal information was collected two weeks before the surgical intervention, including name, age, gender, dental history, medical history, and informed consent. All participants underwent phase I periodontal therapy, which included patient education, oral hygiene instruction, scaling and root surface debridement, mouthwash, and correction of abnormal restoration to obtain optimal infection control. And they were scheduled for a second visit for surgical intervention.

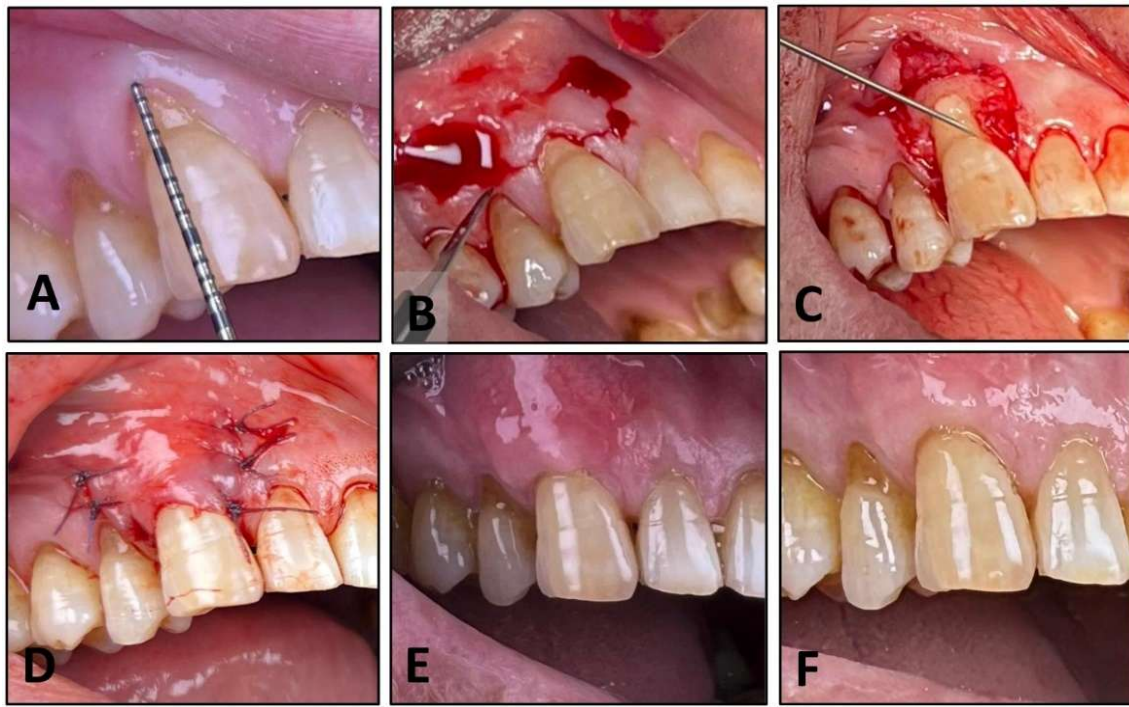
#### Surgical Protocol:

The surgical intervention began with measuring clinical parameters, then injection of local anesthesia, with 2% lidocaine hydrochloride containing adrenaline concentration 1:80000 delivered

to the recipient site. Before the intervention, the patient was instructed to rinse with 0.12% chlorhexidine Digluconate to disinfect the oral cavity for all groups. After adequate anesthesia, the coronally advanced flap technique was performed as described by Zucchelli<sup>[17]</sup>. On the facial aspect of the tooth, two bleeding lines (horizontal incision) were made with a 15c blade extending mesially and distally 3mm long from the recession edge and (recession depth +1mm) from the tip of the interdental papilla, with a note that the interdental papilla that was located coronal to the horizontal incision known as anatomic papilla and the interdental papilla that was located apical to the horizontal incision known as surgical papilla. Then, two

vertical and divergent releasing incisions were extended apically beyond MGJ from the ends of horizontal incisions.

A periosteal elevator was used to raise the flap with split-thickness at the surgical papilla area to provide a blood supply bed and full thickness at the recession area until the bone. Also, a full-thickness flap 2.5-3 mm beyond the bone crest was used to avoid perforation of the thin mucosa in that area. After that, a split thickness flap was used to release tension on the flap bed. Gracey curettes were used for gentle root-planning of the root surface, followed by irrigation and cleaning with abundant normal saline. Figure 2 illustrates the treated sites' pre-surgical, surgical, and post-surgical conditions for group A.



**Figure 2: Pre-surgical, surgical, and post-surgical recipient site treated with CAF + 0.8% HA for Group A. (A) Measurement of clinical parameters, (B) vertical and horizontal incisions for flap elevation. (C) HA is applied to the root surface. (D) Flap suturing. (E) One-month result. (F) Three-month result.**

For group A, hyaluronic acid (8 mL, 0.8% GENGIGEL® forte oral gel, Ricerfarma S.R.L. Milano, Italy) was applied to the denuded root surface with a single-use sterile medical G22 syringe. HA completely covered the root surface.

For group B, hyaluronic acid (20 mL, 0.2% GENGIGEL® GINGIVALGEL, Ricerfarma S.R.L. Milano, Italy) was applied to the denuded root surface with a single-use sterile medical G22 syringe. HA completely covered the root surface.

For the control group C, no materials were applied to the denuded root surface (CAF alone)

Finally, for all groups, the flap was moved coronally and sutured 1-2 mm coronal to CEJ to compensate for the shrinkage after healing. The flap was sutured in place by a single-sling suture and multiple interrupted sutures for vertical incisions. The suture material used was synthetic absorbable PGA (5-0 polyglycolic acid, Yingmed, China) for all groups, due to its minimal tissue response, bacterial growth suppression, high tensile strength (capable of withstanding muscle tension), and resorption rate of between 21 and 28 days<sup>[18]</sup>.

#### Post-Operative Care:

To prevent post-operative infection, edema, and pain control, antibiotics and analgesics (amoxicillin 500mg, metronidazole 500mg, paracetamol 500mg) were prescribed for the patient every 8 h for 7 days. The patient was instructed to rinse twice daily for 45 seconds with a 0.12% chlorhexidine Digluconate solution for 10 days. To prevent unnecessary trauma, the patient was also advised to discontinue tooth brushing for one week and flossing for four weeks at the surgical site. The sutures were removed after 10 days.

#### Blinding and bias control procedures:

Several blinding methods were implemented to minimize the bias. Patients were blinded to their group assignment by using identical syringes or applicators filled with HA gel or no material across all groups. Clinical outcomes were assessed by a calibrated examiner who was blinded to the group allocation and trained in standardized measurement procedures. Prior to the trial, inter-examiner reliability was established through calibration sessions to ensure consistency. The surgeon, however, couldn't be blinded due to the precise technique required for HA gel application, which necessitated visual control and careful manipulation of the material.

#### Outcomes Assessment and Timing:

Clinical parameters, including (RD, WKG, CAL, PPD, PI, and GI), were measured at three time points. Baseline measurements were obtained immediately before surgery, accompanied by standardized intraoral photographs using a fixed camera mount. The first follow-up was conducted  $30 \pm 2$  days postoperatively, during which the same clinical parameters were reassessed and any post-surgical complications (e.g., swelling, pain, infection) were documented. The final follow-up was scheduled at  $90 \pm 5$  days, a time point chosen based on evidence indicating the surgical results were clinically stable and not affected by the maintenance period [19]. At this visit, all clinical parameters were re-evaluated, and root coverage percentage (RC%) was calculated as:

$$CRC(\%) = \frac{RD_{pre-op} - RD_{post-op}}{RD_{pre-op}} \times 100\%$$

To further ensure reliability, 50% of the cases were randomly selected for reassessment by an independent examiner, with the intraclass correlation coefficient (ICC) used to quantify inter-examiner agreement<sup>[20]</sup>.

#### Statistical analyses

The age and gender of the study groups were presented as counts (n) and percentages (%), along with the median and median absolute deviation (MAD), respectively. The comparisons of age and gender among the study groups were analyzed using the Kruskal-Wallis test and the Chi-squared test. Additionally, comparisons of outcomes among groups at baseline and subsequent time periods were assessed using the Kruskal-Wallis test. Pairwise comparisons were conducted with the Steel-Dwass test, which evaluates all pairs. The outcomes, including RD, WKG, PPD, CAL, PI, and GI, were analyzed over time using the Wilcoxon Signed Rank test. A significance level of difference was determined in a  $p < 0.05$ . All statistical analyses were conducted using JMP®,

Version 18.0 (SAS Institute Inc., Cary, NC, 1989–2023).

**RESULT**

Thirty individuals (24 male and 6 female) were recruited and treated between November 2024 and June 2025. No patient in any group had any allergy to the materials used or developed post-operative complications, such as infection or swelling. The study teeth included eight

maxillary canines, five first premolars, and one second premolar, as well as mandibular, five central incisors, five lateral incisors, five canines, and one first premolar.

Participant characteristics at baseline (gender, upper/lower tooth side, and age) showed no significant between-group differences ( $p > 0.05$ ), ensuring comparable groups before initiation of therapy (Table 1).

**Table 1: Participants' characteristics of the study groups at baseline.**

Characteristics	Study groups			P value
	Group C (n=10)	Group B (n=10)	Group A (n=10)	
Gender no (%)				0.5353
Male	7 (70.00)	9 (90.00)	8 (80.00)	
Female	3 (30.00)	1 (10.00)	2 (20.00)	
Tooth side no (%)				0.1173
Lower	4 (40.00)	8 (80.00)	4 (40.00)	
Upper	6 (60.00)	2 (20.00)	6 (60.00)	
Age med (MAD)	38.5 (6.5)	40 (5)	45 (8.5)	0.2923

a Kruskal-Wallis test and the bChi-squared test. Med: Median; MAD: Median Absolute Deviation; CAF: coronally advanced flap; HA: Hyaluronic acid; n: number of patients; P: level of significance,  $p < 0.05$ .

There were no significant between-group differences at baseline in RD, WKG, PPD,

CAL, PI, or GI ( $P > 0.05$ ), as detailed in Table 2.

**Table 2: Comparisons of outcomes among groups at baseline.**

Variables	Group's Median (MAD)			P value
	Group C (n=10)	Group B (n=10)	Group A (n=10)	
RD	3.5 (0.0)	3 (0.25)	3 (0.5)	0.4688
WKG	2.25 (0.25)	2 (0.0)	2.25 (0.25)	0.8454
PPD	1 (0.0)	1 (0.0)	1 (0.0)	0.4148
CAL	4.5 (0.5)	4.25 (0.25)	4 (0.5)	0.4817
PI	0.98 (0.02)	0.96 (0.02)	0.96 (0.04)	0.6762
GI	1 (0.0)	0.98 (0.02)	0.96 (0.02)	0.3398

aKruskal-Wallis test; P: level of significance,  $p < 0.05$ ; RD, WKG, PPD, and CAL measured in mm; MAD: Median Absolute Deviation; PI and GI measured in scores

At three months, all treatments—CAF + 0.8% HA, CAF + 0.2% HA, and CAF alone—produced significant improvements from baseline, with reductions in RD, PPD, CAL, PI, and GI and an increase in WKG ( $p < 0.05$ ; Table 3).

**EFFICACY OF HYALURONIC ACID GEL WITH CORONALLY ADVANCED**

**Table 3: Comparisons of outcomes after three months in each study group.**

Clinical parameters	Group C median			Group B median			Group A median		
	Baseline	3M	P	Baseline	3M	P	Baseline	3M	P
RD	3.5	2.75	0.0020	3	1.75	0.0020	3	1	0.0020
WKG	2.25	3	0.0039	2	3	0.0020	2.25	3.25	0.0020
PPD	1	0.9	0.0156	1	0.5	0.0156	1	0.5	0.0020
CAL	4.5	3.5	0.0020	4.25	2.5	0.0020	4	1.5	0.0020
PI	0.98	0.58	0.0020	0.96	0.58	0.0020	0.96	0.58	0.0020
GI	1	0.56	0.0020	0.98	0.54	0.0020	0.96	0.54	0.0020

a Wilcoxon Signed Rank test; 3M: three months; P: level of significance, p<0.05; RD, WKG, PPD, and CAL measured in mm. PI and GI measured in scores

At 1 and 3 months, intergroup comparisons revealed significant differences in RD, PPD, CAL, and RC% (p < 0.05; Table 4). Group A consistently outperformed Groups B and C, showing the lowest RD (1 mm),

greatest CAL gain (2.5 mm), shallowest PPD (0.5 mm), and highest RC% (66.7%). In contrast, WKG (p = 0.2914), PI, and GI did not differ significantly across groups (p > 0.05).

**Table (4): Comparisons of outcomes among and between study groups after 1 and 3 months**

Outcomes		Group's median (MAD)			P
		Group C (n=10)	Group B (n=10)	Group A (n=10)	
RD	1M	2.75 (0.25)	1.75 (0.25)	1 (0)	0.0003, A < B (p=0.0109), A < C (p=0.0020), B ~ C (p=0.0827)
	3M	2.75 (0.25)	1.75 (0.25)	1 (0)	0.0003, A < B (p=0.0109), A < C (p=0.0020), B ~ C (p=0.0590)
WKG	1M	3 (0.5)	3 (0.25)	3.25 (0.25)	0.2914
	3M	3 (0.5)	3 (0.25)	3.25 (0.25)	0.2914
PPD	1M	0.9 (0.1)	0.5 (0)	0.5 (0)	0.0032, A% < C (p=0.0019), A~ B (p=0.4710), B ~ C (p=0.1689)
	3M	0.9 (0.1)	0.5 (0)	0.5 (0)	0.0017, A< C (p=0.0011), A ~ B (p=0.4573), B ~ C (p=0.1376)
CAL	1M	3.5 (0.5)	2.5 (0.35)	1.5 (0.1)	0.0001, B < C (p=0.0282), A < B (P=0.0102), A < C (p=0.0010)
	3M	3.5 (0.4)	2.5 (0.25)	1.5 (0)	<0.0001, B < C (p=0.0243), A < B (p=0.0032), A < C (p=0.0008)
PI	1M	0.61 (0.03)	0.58 (0)	0.58 (0.04)	0.6529
	3M	0.58 (0.04)	0.58 (0.04)	0.58 (0.05)	0.7339
GI	1M	0.56 (0.06)	0.54 (0.02)	0.54 (0.04)	0.5831
	3M	0.56 (0.06)	0.54 (0)	0.54 (0.04)	0.4742
RC %	3M	15.5 (0.01)	50.0 (0.09)	66.7 (0.06)	0.0006. A > C (p=0.0026), A > B (p=0.0434), B ~ C (p=0.0509)

a Pairwise, Steel-Dwass test; MAD: median absolute deviation; 1M: one month; 3M: three months; P: level of significance, p<0.05; RD, WKG, PPD, and CAL measured in mm. PI and GI measured in scores

**DISCUSSION**

In recent years, HA has emerged as a promising adjunctive agent in dental surgical procedures. The current study

represents the first triple-group randomized clinical trial comparing the efficacy of HA gel at two concentrations (0.8% and 0.2%) as an adjunct to the CAF procedure in the management of Miller Class I gingival

recession, versus a control group (CAF without HA). The study sample was chosen from 18 to 60 years to reflect a population most prone to gingival recession owing to cumulative etiological factors such as plaque accumulation and mechanical trauma, while avoiding severe tissue ageing beyond 60. Also, the study only included Miller Class I recession instances (mild recession without bone or soft tissue loss) to ensure sample homogeneity and minimize confounding variables from anatomical issues such as bone abnormalities in Class III/IV.

At the study's beginning, no statistically significant variations in gender, tooth position, or age existed between the three groups. This enhances the study's credibility, lowering demographic influences on results. Effectiveness variations across groups (e.g., 0.8% HA's superiority) are due to the therapy, not baseline participant characteristics. Also, smokers were excluded to ensure the validity, as nicotine compromises blood perfusion and impedes tissue healing. This aligns with findings by Nanavati (2013), who reported a 15% reduction in root coverage among smokers compared to non-smokers<sup>[21]</sup>.

After 3 months, all groups demonstrated a significant decrease in RD, but Group A had the greatest median (RD) improvement and recession coverage (66.7%), followed by Group B (50%), and Group C (control) (15.5%). High HA concentrations improve tissue hydration, scaffold stability, and prolong the anti-inflammatory and regenerative effects at the surgical site. This is in agreement with findings from Kalimeri (2024), who demonstrated that HA at 0.8% yielded results comparable to those of enamel matrix derivative (EMD), a well-established material in periodontal regeneration<sup>[22]</sup>. However, Group B didn't show a difference over the control group, aligning with the results of Kumar (2014), which demonstrated no statistically

significant outcomes between the test and the control groups, but only clinically.

When examining the width of the keratinized gingiva, no significant variations were found among the groups after three months, and this aligns with that of Saxena (2022). The precise role of hyaluronic acid in promoting keratinization of the overlying mucosa remains unclear, although it may be associated with its function in keratinocyte proliferation.

A similar trend was observed in probing pocket depth among the three. After 3 months, Group A outperformed the control group, but there was no statistical difference between A and B. Khuwaja et al. (2024) discovered that adding 0.8% hyaluronic acid after scaling and root planing reduced PPD much more than the control group. The anti-inflammatory and wound-healing characteristics of HA may minimize pocket depth in non-surgical periodontal treatment and surgical therapies like CAF<sup>[23]</sup>. Clinical attachment level (CAL) improvement was higher in Group A than in the B and C groups in this study. Group B had better CAL gain than group C, demonstrating a concentration-dependent effect of HA on periodontal healing due to its ability to induce fibroblast migration, angiogenesis, and extracellular matrix remodeling.

Numerous studies have shown better root coverage when HA is combined with other biomaterials. After six months, Nandanwar J (2018) discovered that HA combined with a resorbable PLA/PGA membrane achieved 92.93% mean root coverage (MRC). This highlights the need for a physical barrier for wound healing and protection. The cost and complexity of this approach may limit its clinical use<sup>[24]</sup>. Yavuz A (2024) discovered that while applying the coronally advanced flap technique, platelet-rich fibrin (PRF) could perform better than HA regarding root coverage. This indicates the potential superiority of certain biologics in specific circumstances. However, HA doesn't need the preparation of autologous blood and is

inexpensive and simple to use<sup>[25]</sup>. Castro-Calderón A (2022) assessed the non-surgical delivery of HA to improve the appearance of the interdental papilla, highlighting the potential of HA in cosmetic dentistry, but not in functional root covering. Nonetheless, this study aims to restore the function and appearance<sup>[26]</sup>.

#### **Limitations:**

This study has several limitations that should be mentioned; a relatively small sample size limits the generalizability and statistical power of the findings, and a short follow-up period that is sufficient to assess early healing and short-term outcomes, still, it does not reflect the **long-term stability** of root coverage or soft tissue health. Another notable limitation is the lack of histological evaluation that can provide precise insights into tissue attachment and regeneration quality. Furthermore, the study didn't assess the aesthetic outcomes, which are significant in gingival recession cases.

#### **CONCLUSIONS:**

Hyaluronic acid at 0.8% exhibits significant efficacy in root coverage when combined with the CAF approach and may serve as a safe and practical alternative to more costly and complex biomaterials. The findings corroborate that elevated HA concentrations facilitate accelerated tissue healing and enhanced flap stability, especially in Miller class I recession defects. Despite the positive outcomes, the short follow-up duration warrants cautious interpretation, and longer-term studies are needed to validate the stability of these results. Further head-to-head comparisons between HA and other regenerative materials (e.g., PRF, EMD, or bioresorbable membranes) are needed to determine the optimal treatment modality for each clinical scenario.

#### **RECOMMENDATIONS:**

Future work should consider a large sample size to enhance the generalizability and statistical power of the findings. Long-term

follow-up periods are necessary to assess the stability of results. Histological evaluation is required to verify proper periodontal regeneration and understand the biological mechanisms through which hyaluronic acid contributes to healing. Finally, incorporating aesthetic outcome measures and patient-reported satisfaction scores will help provide a more comprehensive view of treatment success.

#### **Declarations**

#### **Conflict of interest:**

The article authors declare that they have no conflicts of interest in the submitted manuscript.

#### **Acknowledgments:**

Not applicable

#### **REFERENCES**

1. Abdel Aziz MA, Amer A-FM, Hosny M. Coronally advanced flap in conjunction with hyaluronic acid application to treat localized gingival recession. *Al-Azhar Journal of Dental Science*. 2023;26(4):539-45. <https://dx.doi.org/10.21608/ajdsm.2022.119329.1299>
2. Katti N, Kp R, Barik AK, Das SK, Peri S, Mohanty D. Enhancing root coverage and esthetic outcomes in isolated gingival recession using orthodontic intervention and lateral closed tunnel technique: An interdisciplinary prospective case series. *Clinical Advances in Periodontics*. 2025;15(1):14-24. <https://doi.org/10.1002/cap.10285>
3. Bhatia A, Yadav VS, Tewari N, Kumar A, Sharma RK. Efficacy of modified coronally advanced flap in the treatment of multiple adjacent gingival recessions: a systematic review and meta-analysis. *Acta odontologica Scandinavica*. 2021;79(8):562-72. <https://doi.org/10.1080/00016357.2021.1908594>
4. González-Febles J, Romandini M, Laciari-Oudshoorn F, Noguerol F, Marruganti C, Bujaldón-Daza A, et al. tunnel vs.

- coronally advanced flap in combination with a connective tissue graft for the treatment of multiple gingival recessions: a multi-center randomized clinical trial. *Clinical Oral Investigations*. 2023;27(7):3627-38. <https://doi.org/10.1007/s00784-023-04975-7>
5. Marinho A, Nunes C, Reis S. Hyaluronic acid: A key ingredient in the therapy of inflammation. *Biomolecules*. 2021; 11(10). <https://doi.org/10.3390/biom11101518>
  6. Hejran AB, Ashrafi H, Baseer AQ, Sarwari A, Monib AW, Hassand MH, et al. The importance of hyaluronic acid in biological Systems. *European Journal of Theoretical and Applied Sciences*. 2024;2(2):730-43. DOI: 10.59324/ejtas.2024.2(2).65
  7. Pilloni A, Schmidlin PR, Sahrman P, Sculean A, Rojas MA. Effectiveness of adjunctive hyaluronic acid application in coronally advanced flap in Miller class I single gingival recession sites: a randomized controlled clinical trial. *Clinical oral investigations*. 2019;23:1133-41. <https://doi.org/10.1007/s00784-018-2537-4>
  8. Saxena A, Bhusari P, Singh A, Nagi R, Chaturvedi SS. Coronally advanced flap with and without hyaluronic acid (hyaloss) for the treatment of gingival recession—a randomized clinical trial. *Journal of Oral Medicine and Oral Surgery*. 2022;28(4):48. <https://doi.org/10.1051/mbcb/2022034>
  9. Kumar R, Srinivas M, Pai J, Suragimath G, Prasad K, Polepalle T. Efficacy of hyaluronic acid (hyaluronan) in root coverage procedures as an adjunct to coronally advanced flap in Millers Class I recession: A clinical study. *Journal of Indian Society of Periodontology*. 2014;18(6):746-50. DOI: 10.4103/0972-124X.147411
  10. Mamajiwala AS, Sethi KS, Raut CP, Karde PA, Mamajiwala BS. Clinical and radiographic evaluation of 0.8% hyaluronic acid as an adjunct to open flap debridement in the treatment of periodontal intrabony defects: randomized controlled clinical trial. *Clinical Oral Investigations*. 2021;25:5257-71. <https://doi.org/10.1007/s00784-021-03834-7>
  11. D'Silva E, Fraser D, Wang B, Barmak AB, Caton J, Tsigarida A. The association between gingival recession and buccal bone at maxillary anterior teeth. *Journal of Periodontology*. 2020;91(4):484-92. <https://doi.org/10.1002/JPER.19-0375>
  12. Hamasni FM, El Hajj F. Correlations between width of keratinized gingiva and supracrestal gingival tissues dimensions: a retrospective clinical study. *The Journal of Contemporary Dental Practice*. 2021;22(1):18-22. DOI: 10.5005/jp-journals-10024-3022
  13. Salvi GE, Rocuzzo A, Imber JC, Stähli A, Klinge B, Lang NP. Clinical periodontal diagnosis. *Periodontology 2000*. 2023. DOI: 10.1111/prd.12487
  14. Farook FF, Alodwene H, Alharbi R, Alyami M, Alshahrani A, Almohammadi D, et al. Reliability assessment between clinical attachment loss and alveolar bone level in dental radiographs. *Clinical and Experimental Dental Research*. 2020;6(6):596-601. DOI: 10.1002/cre2.324
  15. Silness J, Löe H. Periodontal disease in pregnancy II. Correlation between oral hygiene and periodontal condition. *Acta odontologica Scandinavica*. 1964;22(1):121-35. <https://doi.org/10.3109/00016356408993968>
  16. Löe H. The gingival index, the plaque index and the retention index systems. *The Journal of Periodontology*. 1967;38(6):610-6.

- <https://doi.org/10.1902/jop.1967.38.6.610>
17. Walkar S, Rakhewar P, Chacko L, Pawar S. Zucchelli's Modified coronally advanced flap technique for the treatment of multiple recession defects – A case report. *IOSR Journal of Dental and Medical Sciences*. 2017;16:57-61. DOI: 10.9790/0853-1604065761
  18. Dennis C, Sethu S, Nayak S, Mohan L, Morsi Y, Manivasagam G. Suture materials—current and emerging trends. *Journal of Biomedical Materials Research Part A*. 2016;104(6):1544-59. <https://doi.org/10.1002/jbm.a.35683>
  19. Zucchelli G, Mele M, Stefanini M, Mazzotti C, Mounssif I, Marzadori M, et al. Predetermination of root coverage. *Journal of periodontology*. 2010;81(7):1019-26. doi: 10.1902/jop.2010.090701
  20. Koo TK, Li MY. A guideline of selecting and reporting intraclass correlation coefficients for reliability research. *Journal of chiropractic medicine*. 2016;15(2):155-63. <https://doi.org/10.1016/j.jcm.2016.02.012>.
  21. Nanavati B, N VB, Jaydeepchandra M. Coronally positioned flap for root coverage: Comparison between smokers and nonsmokers. *Journal of International Oral Health: JIOH*. 2013;5(2):21-7.
  22. Kalimeri E, Rocuzzo A, Stähli A, Oikonomou I, Berchtold A, Sculean A, et al. Adjunctive use of hyaluronic acid in the treatment of gingival recessions: a systematic review and meta-analysis. *Clinical oral investigations*. 2024;28(6):329. <https://doi.org/10.1007/s00784-024-05701-7>
  23. Khuwaja SH, Soomro SP, Anwar K, Ifran N, Ahmed A. Clinical evaluation of 0.8% hyaluronic acid gel adjunctive to scaling and root planning in the treatment of chronic periodontitis in hyderabad Sindh. *The Professional Medical Journal*. 2024;31(05):806-11. <https://doi.org/10.29309/TPMJ/2024.31.05.7828>
  24. Nandanwar J, Bhongade ML, Puri S, Dhadse P, Datir M, Kasatwar A. Comparison of effectiveness of hyaluronic acid in combination with polylactic acid/polyglycolic acid membrane and subepithelial connective tissue graft for the treatment of multiple gingival recession defects in human: A clinical study. *Journal of Datta Meghe Institute of Medical Sciences University*. 2018;13(1). DOI: 10.4103/jdmimsu.jdmimsu\_39\_18
  25. Yavuz A, Güngörmek HS, Kuru L, Doğan BJCOI. Treatment of multiple adjacent gingival recessions using leucocyte-and platelet-rich fibrin with coronally advanced flap: A 12-month split-mouth controlled randomized clinical trial. *Clin Oral investig*. 2024;28(5):291. <https://doi.org/10.1007/s00784-024-05694-3>
  26. Castro-Calderón A, Rocuzzo A, Ferrillo M, Gada S, González-Serrano J, Fonseca M, et al. Hyaluronic acid injection to restore the lost interproximal papilla: a systematic review. *Acta odontologica Scandinavica*. 2022;80(4):295-307. <https://doi.org/10.1080/00016357.2021.2007282>.

## پوخته

## کاریگه‌ریا جل ترشی هیالورنیک وهك هۆكاره‌کی هاریکار بو کردارا لڤینا مینایا (تاجا) پیشكه‌فتی د چاره‌سه‌ر کرنا گریدانا پدی: تاقیکرنه‌کا ته‌خته‌به‌ندی یا به‌ره‌لا

**پیشه‌کی و نارمانج:** زارافی گریدانا پدی نامازه ب وئ چهندی دکه تکو دیاربوونا رها ددانی ژ نه‌جامی ژ جه چوونا نیفا پدی به ژ سه‌ری کو جیس و مینا بگه‌هنه نیک. نه‌مژێ دبیته نه‌گه‌ری ناریشه‌یین جوانیی و زیده‌بوونا کرمیبوونی د رهندا و هه‌ستیاربوونا ددانان. نارمانجا فی فه‌کولینی هه‌لسه‌نگاندنا کاریگه‌ریا جل هیالورنیکه (Hyaluronic acid) وهك چاره‌سه‌ر کرنا ته‌مامکار بو چیکرنا لڤینن مینایا پیشكه‌فتی (Coronally advanced flap) دچاره‌سه‌ر کرنا گریدانا پدی.

**که‌ره‌سه‌هه‌ریک:** فه‌کولینا نوکه ل سه‌ر (30) نه‌خوشان هاته کرن (24 نیر و 6 مئ) کو توشی گریدانا پدی بوینه > 2 مم (پولینکرنا میله‌ر یا نیک) ب ناقتجیا ته‌مه‌نین دنایه‌را 18 سالیی هه‌تا 60 سالیی، بشیوه‌کی به‌ره‌لا نه‌خوش ل سه‌ر سی کومه‌لان هاته دابه‌شکرن:

کومه‌لا تاقیکرنا نیک (ژمارا وان = 10) ب لڤاندنا مینایا پیشكه‌فتی (CAF) هاته چاره‌سه‌ر کرنا نه‌وژی ب دانانا جل جینجیل فورتی بی ده‌فی ب چراتیا (0.8%) ترشی هیالورنیک (HA) ل سه‌ر رویی رها دیار ل ده‌می نشته‌ر گه‌ریی.

کومه‌لا تاقیکرنا دووی (ژمارا وان = 10) ب لڤاندنا مینایا پیشكه‌فتی (CAF) هاته چاره‌سه‌ر کرنا، نه‌وژی ب دانانا جل جینجیل بی پدی ب چراتیا (0.2%) ترشی هیالورنیک (HA) ل سه‌ر رویی رها دیار ل ده‌می نشته‌ر گه‌ریی. کومه‌لا کونترولکرنی (ن = 10) هاته چاره‌سه‌ر کرنا بکار نینانا لڤاندنا مینایا پیشكه‌فتی (CAF) بی بجه نینانا هه‌ر که‌ره‌سه‌هه‌ریک زیده‌بار. هه‌می پنه‌مین ته‌خته به‌ندی هاته پیفان، دگه‌لدا کویراتیا گریدانی (RD). و ل ده‌سپیک پدیا رهق (WKG) و کویراتیا به‌ریکا دیار (PPD) و ناستی هه‌فه‌ندی ته‌خته‌به‌ندی (CAL)، و نیشاندهری تابلیی (PI) و نیشاندهری پدی (GI) هاته نیشاندان و هه‌ر هه‌فه‌کی یان سی هه‌یفان لدویف چوون بو بیته کرن.

**نه‌جام:** هه‌ر سی کومه‌ل بشیوه‌یه‌کی مه‌زن ( $p < 0.05$ ) دژیک جودا بوون و کومه‌لا تاقیکرنی (0.8%) باشیوه‌نه‌کا مه‌زتر دیارکر.

**ده‌ره‌نه‌جام:** ترشی هیالورنیک ب ریژمیا (0.8%) کاریگه‌ریه‌کا مه‌زن دیارکر د داگرتنا رها و کیمکرنا کویراتیا گریدانی ب به‌راوردکرنا ب ریژمیا (0.2%) ل ده‌می بکار نینانا زئ دگه‌ل ته‌کنیکا لڤینا مینایا پیشكه‌فتی (CAF) د ناریشه‌یین میله‌ر دا ژ چووی نیک.

## الخلاصة

فعالية جل حمض الهيالورونيك كعامل مساعد لإجراء الشريحة المزاحة تاجيا في علاج انحسار اللثة:  
تجربة سريرية عشوائية محكمة

**الخلفية والأهداف:** يشير انحسار اللثة إلى انكشاف سطح جذر السن نتيجة لازاحة الحافة اللثوية باتجاه ذروي بعيدا عن ملتقى الميناء والملاط، مما يؤدي إلى مشاكل جمالية وزيادة في قابلية الإصابة بالتسوس الجذري والحساسية السنية. يهدف هذا البحث إلى تقييم فعالية جل حمض الهيالورونيك كعامل مساعد لإجراء الشريحة المزاحة تاجيا (CAF) في علاج انحسار اللثة.

**المواد والطرق:** أجريت هذه الدراسة على ثلاثين مريضا يتمتعون بصحة جهازية جيدة (24 ذكر 6 إناث) تتراوح أعمارهم بين 18 و60 سنة، ويعانون من انحسار لثوي موضعي بمقدار  $\leq 2$  ملم (الدرجة الأولى حسب تصنيف ميلر). تم تقسيم المشاركين عشوائيا إلى ثلاث مجموعات:

المجموعة الاختبارية الأولى (العدد=10): تم العلاج بتقنية الشريحة المزاحة تاجيا مع تطبيق جل Gengigel forte بتركيز 0.8% من حمض الهيالورونيك على سطح الجذر المكشوف أثناء العملية.

المجموعة الاختبارية الثانية (العدد=10): تم العلاج بتقنية الشريحة المزاحة تاجيا مع تطبيق جل gingival Gengigel gel بتركيز 0.2% من حمض الهيالورونيك على سطح الجذر المكشوف أثناء العملية.

المجموعة الضابطة (العدد=10): تم العلاج بتقنية الشريحة المزاحة تاجيا فقط دون استخدام أي مواد إضافية تم قياس جميع المعايير السريرية، بما في ذلك عمق الانحسار، و عرض اللثة المتقرنة، وعمق الجيب اللثوي، ومستوى الارتباط السريري، ومؤشر اللويحة، ومؤشر اللثة، وذلك قبل العملية، وبعد شهر، وبعد ثلاثة أشهر من العلاج.

**النتائج:** أظهرت النتائج وجود فروق ذات دلالة إحصائية بين المجموعات الثلاث ( $p < 0.05$ )، حيث سجلت مجموعة الاختبار التي استخدم فيها جل حمض الهيالورونيك بتركيز 0.8% أفضل تحسن من حيث تغطية الجذر وتقليل عمق الانحسار.

**الاستنتاج:** أظهر حمض الهيالورونيك بتركيز 0.8% فعالية أعلى في تغطية الجذور وتقليل عمق انحسار اللثة مقارنة بتركيز 0.2% عند استخدامه كعامل مساعد مع تقنية الشريحة المزاحة تاجيا في علاج حالات انحسار اللثة من الدرجة الأولى حسب تصنيف ميلر.